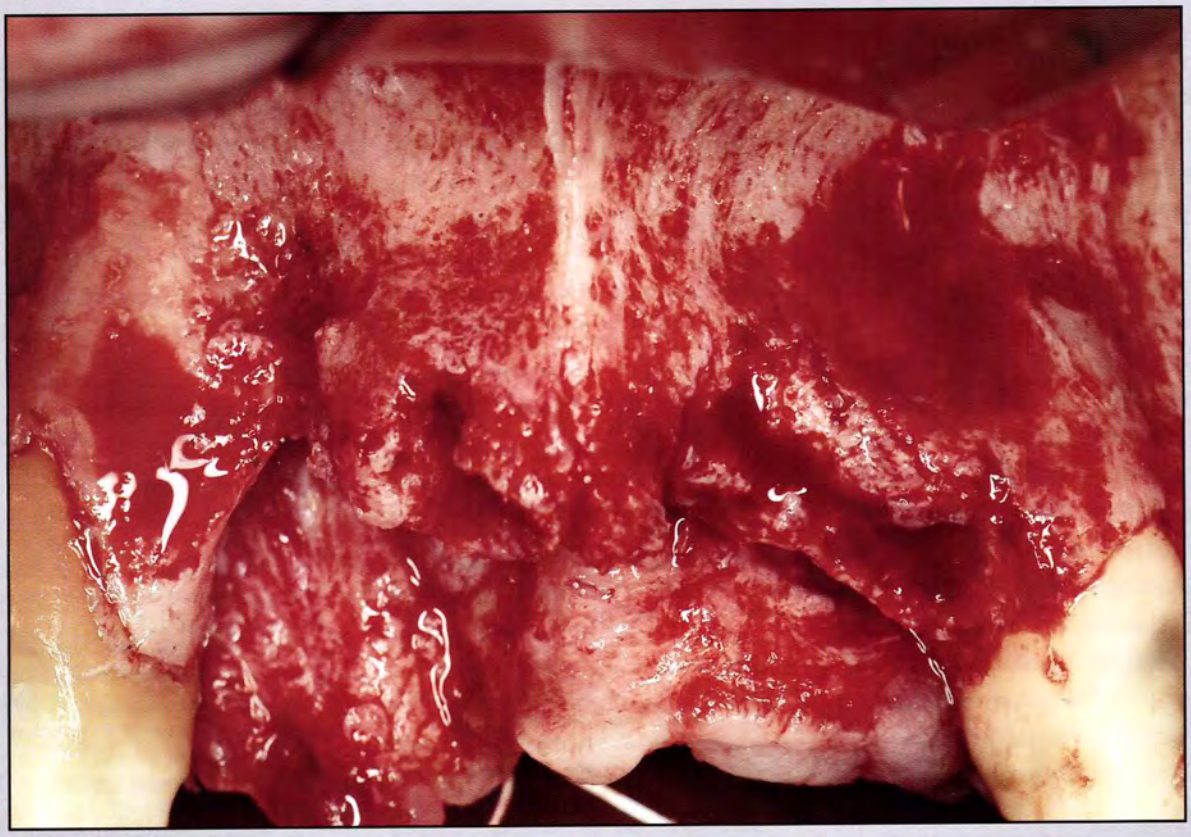

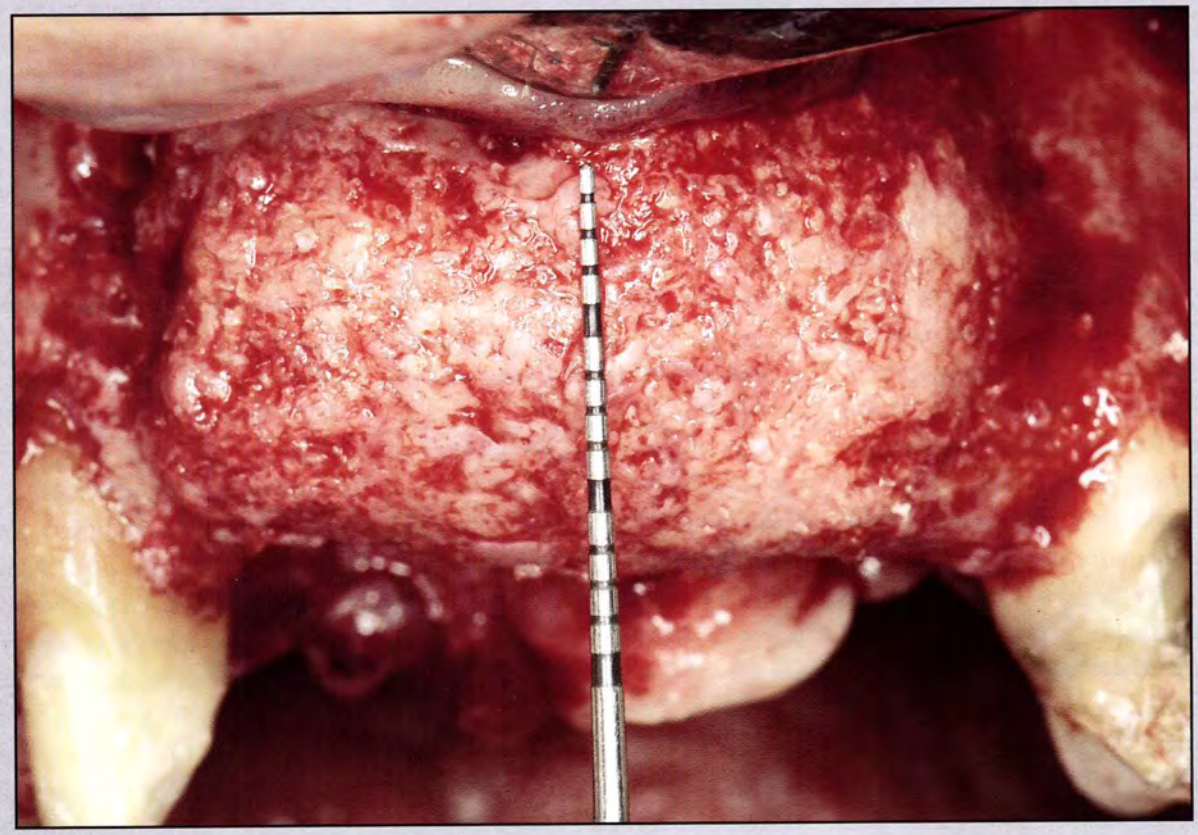

Surgical Management of Significant Maxillary Anterior Vertical Ridge Defects

Istvan A. Urban, DMD, MD, PhD[1]
Alberto Monje, DDS[2]*/Myron Nevins, DDS*[3]
Marc L. Nevins, DMD, MSc[4]*/Jamie L. Lozada, DDS, MS*[5]
Hom-Lay Wang DDS, MSD, PhD[6]

Severe vertical ridge deficiency in the anterior maxilla represents one of the most challenging scenarios in bone regeneration. Under ideal circumstances, guided bone regeneration in combination with soft tissue management has shown predictable esthetic and functional outcomes. Success largely relies on primary wound closure during and after the surgical procedure. Surgical sites present different challenges that need to be considered when designing the flap. The goal of this article is to propose a classification of flap designs that considers vestibular depth and scar formation around the periosteum when performing vertical ridge augmentation in the atrophic anterior maxilla. The four clinical conditions proposed under this classification are (1) shallow vestibule with healthy periosteum, (2) deep vestibule with healthy periosteum, (3) shallow vestibule with scarred periosteum, and (4) deep vestibule with scarred periosteum. The classification will allow clinicians to achieve tension-free closure and more predictable vertical bone gain.
Int J Periodontics Restorative Dent 2016;36:329–337. doi: 10.11607/prd.2644

[1]Assistant Professor, Graduate Implant Dentistry, Loma Linda University, Loma Linda, California, USA; Urban Regeneration Institute, Budapest, Hungary.
[2]Graduate Student, Graduate Periodontics, Department of Periodontics and Oral Medicine, School of Dentistry, University of Michigan, Ann Arbor, Michigan, USA.
[3]Associate Clinical Professor, Division of Periodontology, Department of Oral Medicine, Infection and Immunity, Harvard School of Medicine, Boston, Massachusetts, USA.
[4]Associate Clinical Professor, Division of Periodontology, Department of Oral Medicine, Infection and Immunity, Harvard School of Medicine, Boston, Massachusetts, USA.
[5]Professor, Department of Restorative Dentistry, Director of Graduate Implant Dentistry, Loma Linda University, Loma Linda, California, USA.
[6]Professor and Director of Graduate Periodontics, Department of Periodontics and Oral Medicine, School of Dentistry, University of Michigan, Ann Arbor, Michigan, USA.

Correspondence to: Dr Istvan A. Urban, Director, Urban Regeneration Institute, Sodras utca 9, Budapest, 1026 Hungary. Fax: +36-1-2004447. Email: Istvan@implant.hu

©2016 by Quintessence Publishing Co Inc.

Although recent advances in biomaterials and development of novel techniques have made implant dentistry and guided bone regeneration (GBR) more predictable, vertical ridge augmentation (VRA) remains a potential challenge due to the complexity of hard and soft tissue management. In the anterior maxilla, vertical implant site development is targeted as an optimal long-term esthetic outcome. As an alternative to block grafting or distraction osteogenesis in targeting these demands, GBR has been demonstrated to overcome severe vertical ridge atrophy.[1–6] Space can be created and maintained through the use of a moldable and form-stable barrier membrane in combination with a bone substitute capable of building up a robust biologic structure mimicking native tissues. Nonresorbable titanium-reinforced polytetrafluoroethylene (PTFE) barrier membranes fulfill the above criteria and have been suggested to achieve successful VRA in large defects.[7,8]

Primary tension-free closure during the surgery and healing phase remains the key to predictability in successful VRA.[9] Flap design holds the solution. A flap that is too small is difficult to manage and is often responsible for early membrane or graft exposure that leads to poor clinical outcomes.[10,11]

Table 1 Classification and Description of Defects to Achieve Tension-Free Flap Closure in Anterior Maxillary VRA Procedures

Classification	VRA[a]	Horizontal ridge deficiency	Previous attempt	Vestibule	Periosteum	Proposed flap management	Difficulty[b]
Type I	Shallow to moderate	Maybe	No	Deep	Native	Remote flap + periosteal incision + separation of elastic fibers + double-layer suture	Easy
Type II	Severe	Yes	Maybe	Shallow	Native	Safety flap + papilla shift technique + suborbicularis preparation + double-layer suture	Difficult
Type III	Shallow to moderate	Maybe	Yes	Deep	Scarred	Remote flap + periosteal incision with periosteoplasty + separation of elastic fibers + double-layer suture	Moderate
Type IV	Moderate to severe	Maybe	Yes	Shallow	Scarred	Safety flap + periosteal incision with periosteoplasty + papilla shift technique or periosteal excision + separation of elastic fibers + double-layer suture	Difficult

VRA = vertical ridge augmentation.
[a]Shallow ≤ 4 mm; moderate = 4–6 mm; severe ≥ 6 mm.
[b]Difficulty with adequate preparedness and armamentarium.

Previous surgical attempts and the use of different graft materials might alter the quantity and quality of the soft tissues via translocation of the vestibule and consequent loss of depth. Scarring of the periosteum may affect its thickness and elasticity, which can impair flap advancement.

The experience of the authors has demonstrated that the clinical decision regarding flap design and management is based on two major factors: (1) depth of the vestibule and (2) periosteum quality/integrity.

The goals of this article are to provide a classification based on four clinical scenarios and to propose techniques to assist clinicians in achieving tension-free flap closure during VRA of the anterior atrophic maxilla (Table 1).

Anterior Maxillary Vertical Ridge Augmentation Flap Design Classification

Type I: Deep vestibule and native periosteum

Indication

Patients with shallow to moderate vertical defects (up to 6 mm) or horizontal defects usually present with a normal vestibular depth, a good amount of keratin thickness (KT), and an intact, native periosteum.

Technical note

A remote flap should be used, and this design consists of crestal and vertical releasing incisions. A full thickness midcrestal incision is typically used in the keratinized gingiva with a #15c surgical scalpel. For surgical access, the two divergent vertical incisions are placed at least one tooth away from the surgical site. The maximum distance of the vertical incisions is two teeth away from the defect. In general, a larger flap will be easier to close and will result in less mucogingival junction (MGJ) distortion. After the primary incisions, periosteal elevators are used to reflect a full thickness flap beyond the MGJ and at least 5 mm beyond the bone defect. A palatal remote flap is also used, consisting of sulcular and two palatal vertical releasing incisions of about 6 to 8 mm in length placed at the distal line angles of the neighboring teeth. An appropriately sized titanium-reinforced membrane is selected and trimmed so that it totally covers the volume of the graft and the edges of the membrane will not be in contact with the natural teeth. The membrane should rest on at least 2 mm of the adjacent bone.

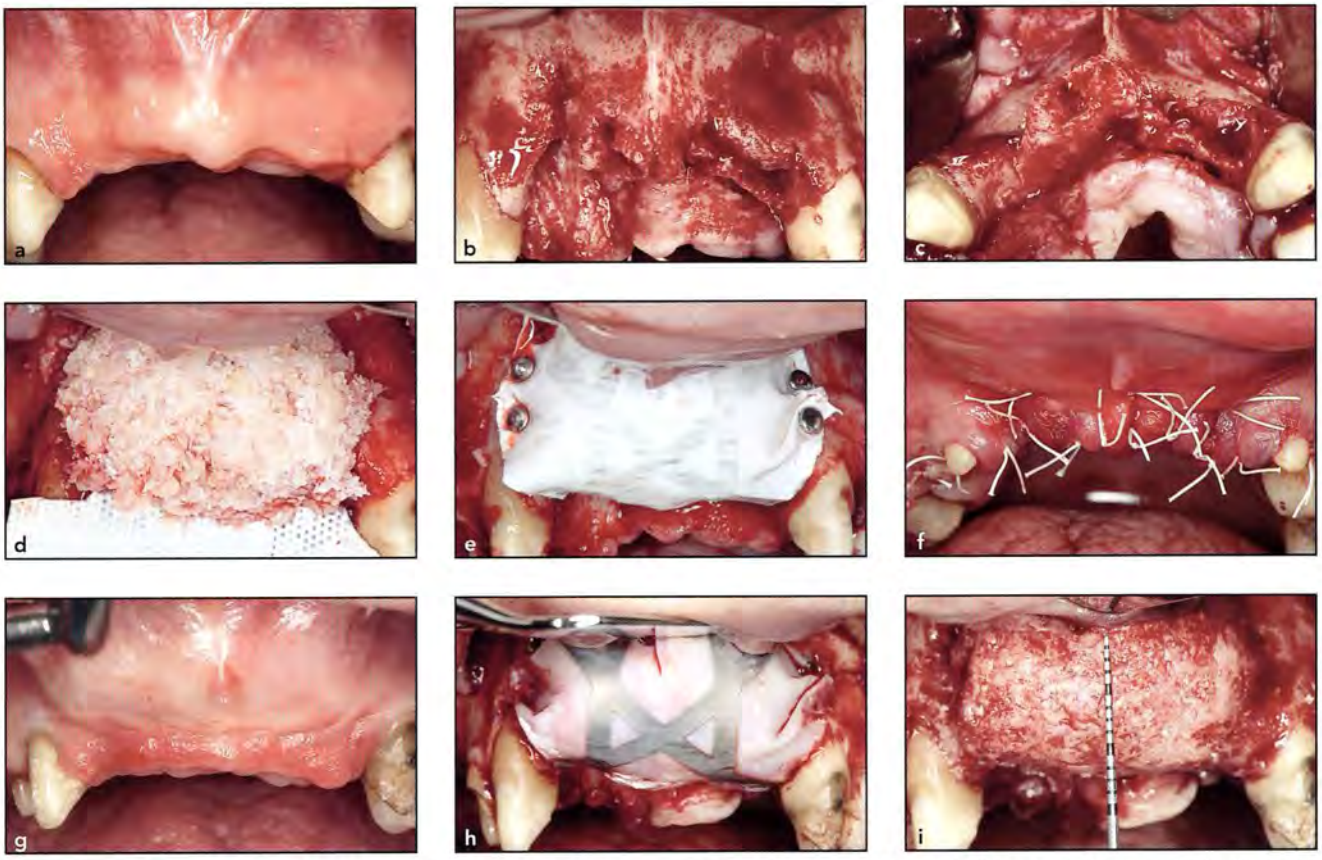

Fig 1 Type I: *Deep vestibule and native periosteum.* (a) *Frontal view. Note the adequate presence of KM and the deep vestibule.* (b) *Bony architecture displaying a moderate vertical bone atrophy.* (c) *Occlusal view of the defect.* (d) *Placement of particulated anorganic bovine bone combined with autogenous graft (1:1 ratio).* (e) *Placement and stabilization of titanium-reinforced PTFE membrane to contain the defect.* (f) *Horizontal mattress and single interrupted sutures.* (g) *Clinical outcome after healing. Adequate vertical and horizontal bone augmentation are achieved in the presence of proper KM and vestibule depth.* (h) *Surgical reentry at 9 months.* (i) *Successful vertical and horizontal bone augmentation.*

Membrane fixation is a critical aspect of this procedure since the graft must be immobile for incorporation. The membrane is fixated first on the lingual/palatal sides using titanium pins or 3-mm titanium screws on at least two points. The bone graft is then placed into the defect and the membrane is folded over and fixed with additional titanium pins or screws. The membrane has to be placed to account for the future bone height and width, and the graft has to completely fill the created space to support the membrane (Fig 1).[5,6,12]

Tips and pearls

Flap advancement/Double-layer suturing

Once the membrane is completely secured, the flap must be mobilized to permit tension-free, primary closure. The flap release is performed in two stages.

1. **Periosteal incision:** First, using a new blade, the periosteum is sharply cut to connect the two vertical incisions.
2. **Separation of the elastic fibers:** Once the elastic fibers are reached, the separation of these fibers is carried out via a more blunt dissection. This can be achieved with periosteal instruments pulling in a coronal motion. Alternatively, scissors in an opening motion or 90-degree-rotated scalpels in a sweeping motion can also be used. Once the separation of the elastic fibers is achieved, the flap is released and can be sutured tension free. The flap is then sutured in two layers. The first layer is closed with horizontal mattress sutures

placed 4 mm from the incision line, and then single interrupted sutures are used to close the edges of the flap. With this technique, the flap margins become averted, effectively abutting the 4-mm-wide inner connective tissue layers of the buccal and lingual flaps. This intimate connective-tissue-to-connective-tissue contact provides a barrier preventing exposure of the membrane.

Preferably, an e-PTFE suture (eg, GORE-TEX CV-5 Suture, W.L. Gore & Associates or Cytoplast 3-0, Osteogenics) is used for suturing. The vertical incisions are closed with single interrupting sutures, starting from the apical area and continuing to the crestal area.

Type II: Shallow vestibule and native periosteum

Indication

In this type of deformity, the patient has a shallow vestibule either because of a severe vertical ridge deficiency or from a previous surgical procedure that has translocated the MGJ without scarring the periosteum. With the latter, it is possible to perform a free soft tissue graft for vestibular deepening and transform the defect to a Type I and continue as a Type I. However, severe vertical defect cases should be treated as described below.

Technical note: The free curtain flap and papilla shift technique

In this type of defect, an extended remote flap called the safety flap (SF) should be used. The flap design is at least one tooth larger than in the Type I case. The two vertical incisions are made two, three, or even four teeth away from the defect depending on the severity of the vertical defect. In this technique, after periosteal incisions and elastic fiber separation, the clinician can laterally position the remote areas of the flap (referred to as the "free curtain flap") and shift each papilla mesially to overcome the shortcomings of the shallow vestibule. This combination of coronally and laterally positioned flap is called the papilla shift technique (Fig 2).

Tips and pearls

In extreme cases, the internal preparation of the flap under the periosteum can be carried out anteriorly close to the lip below the orbicularis muscle without damaging its fibers. With this flap, coronal manipulation is called the "suborbicularis preparation" and soft tissue can be gained from both the coronal and lateral regions.

The suturing begins in the middle of the defect with a mattress suture, which then continues with pulling the distal papilla of the next tooth mesially to close the distal area of the ridge defect. The distal vertical incisions are sutured beginning with the apical part. In these cases, the apical mucosal part of the vertical incision is frequently pulled down to the tooth margin, resulting in a localized mucogingival distortion at the most distal tooth involved in the flap. The rest of the suturing is performed as described previously.

Type III: Deep vestibule and scarred periosteum

Indication

Patients with shallow to moderate vertical defects who underwent previous bone graft attempts that scarred the periosteum but did not significantly change the MGJ may fall into this category. The authors have found that this type of anterior maxilla is unusual, since in most cases the regenerative attempts also distort the MGJ.

Technical note

Flap design should be planned as in Type I defects. However, the periosteal release incision is different because the periosteum is thickened and scarred, decreasing the chances of reaching optimal elasticity of the flap. In this case, a periosteoplasty[13] or a partial excision of the periosteum should be performed. A single incision is performed at the line connecting the apical ends of the vertical incisions. The depth of this incision is dependent on the thickness of the periosteum, but in general it should reach the elastic fibers. It is then continued coronally as an internal partial thickness incision, detaching the scarred periosteum from the deeper elastic fibers. Care must be taken not to perforate the flap during the manipulation. The flap then becomes elastic and can be advanced and closed into its desired position. In extreme cases, the internal preparation of the flap under the periosteum can be carried out close to the lip below the orbicularis muscle without damaging its fibers. In cases where the

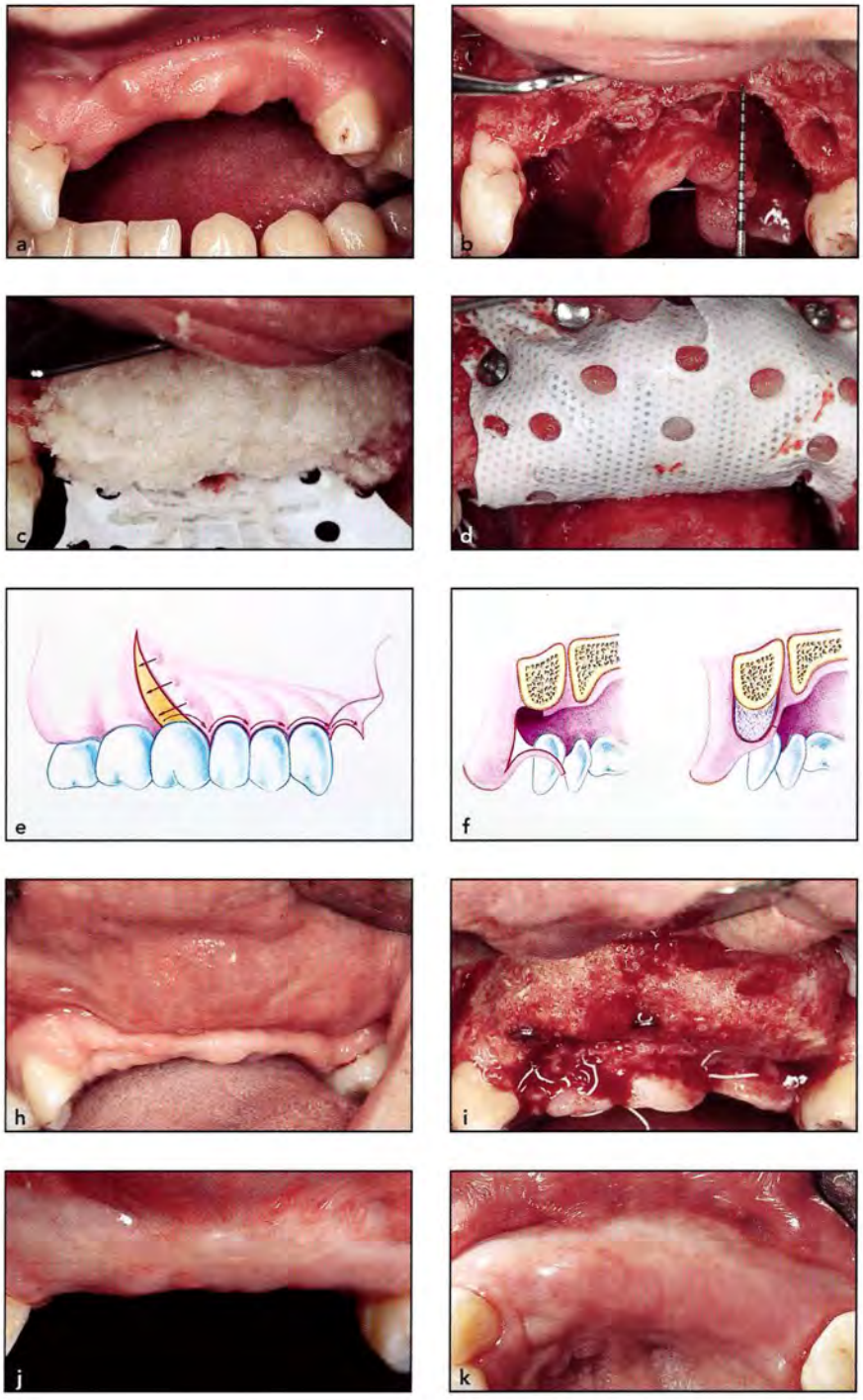

Fig 2 Type II: *Representative case of shallow vestibule and native periosteum.* (a) *Labial view of a patient with advanced vertical defect and loss of the vestibule.* (b) *Labial view of the vertical bone deficiency. A safety flap was created with two vertical incisions placed three teeth behind the deficient ridge.* (c) *Labial view of the bone graft in place.* (d) *Labial view of the titanium-reinforced PTFE membrane in place.* (e) *Schematic drawing representing papilla shift technique. Note that while the papillae are shifted mesially, the vertical incisions are closed distally.* (f) *Lateral view of the final flap preparation using the suborbicularis. Final soft tissue closure after bone grafting.* (g) *A combination of papilla shift technique and suborbicularis muscle preparation was performed* (arrows). *The double layer suturing technique secures and stabilizes the grafting for adequate healing.* (h) *Occlusal view of uneventful healing after 9 months. Note: tooth 12 was extracted due to a fracture of the tooth.* (i). *Labial view of the regenerated ridge.* (j) *Labial and* (k) *occlusal views of the reconstructed anterior maxilla after vertical ridge augmentation and soft tissue reconstructive surgery. Keratinized tissue is visible and the vestibule has been reconstructed.*

clinician feels that the undermined periosteum is thin or was damaged during the internal preparation and will not survive, a partial excision of the scarred periosteum is recommended. The closure is performed as in Type I. Suturing of the undermined periosteum is not recommended as hinging and then pulling the periosteum with sutures may strangle it, which could result in soft tissue healing complications (Fig 3).

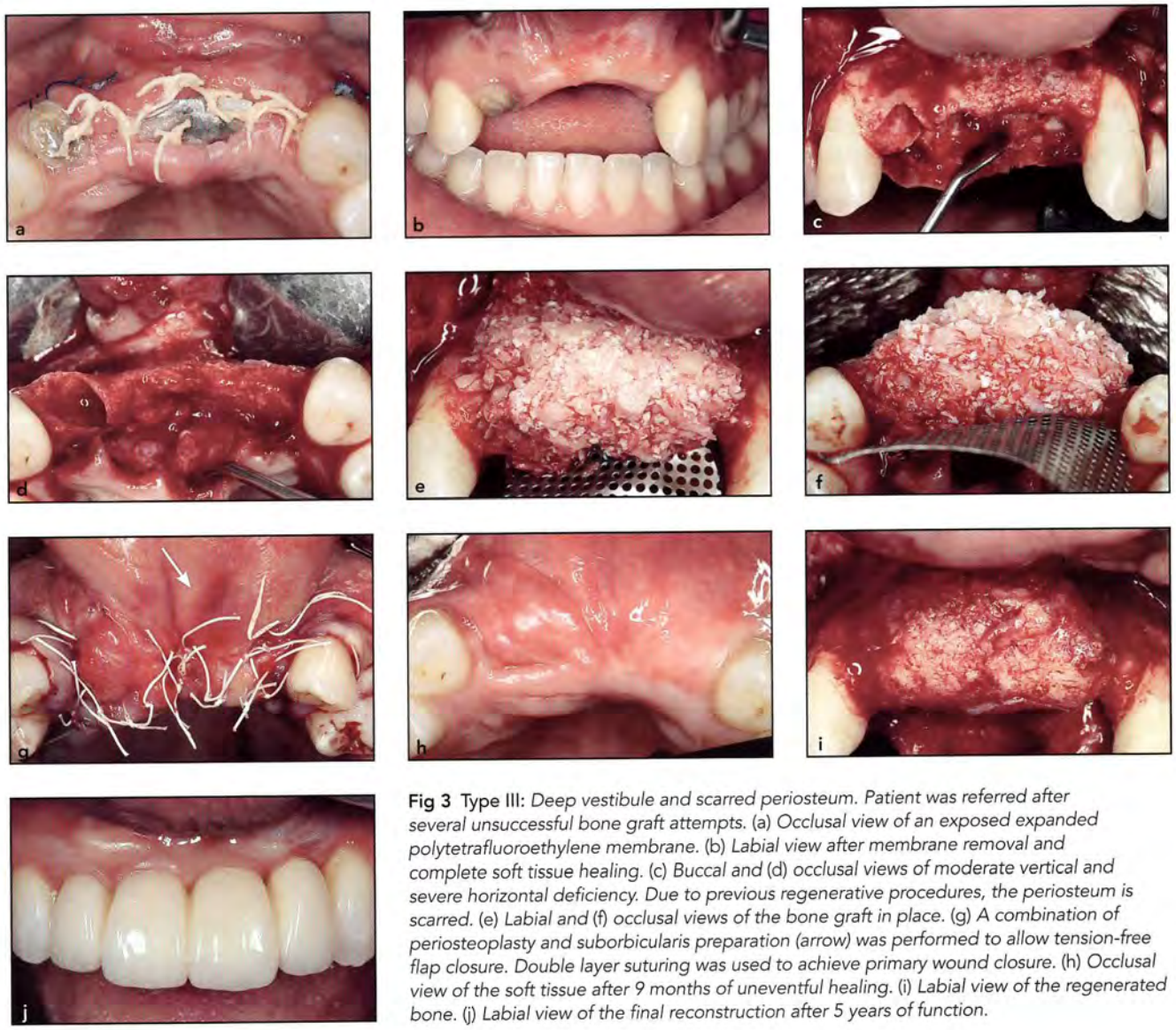

Fig 3 Type III: *Deep vestibule and scarred periosteum. Patient was referred after several unsuccessful bone graft attempts.* (a) *Occlusal view of an exposed expanded polytetrafluoroethylene membrane.* (b) *Labial view after membrane removal and complete soft tissue healing.* (c) *Buccal and* (d) *occlusal views of moderate vertical and severe horizontal deficiency. Due to previous regenerative procedures, the periosteum is scarred.* (e) *Labial and* (f) *occlusal views of the bone graft in place.* (g) *A combination of periosteoplasty and suborbicularis preparation (arrow) was performed to allow tension-free flap closure. Double layer suturing was used to achieve primary wound closure.* (h) *Occlusal view of the soft tissue after 9 months of uneventful healing.* (i) *Labial view of the regenerated bone.* (j) *Labial view of the final reconstruction after 5 years of function.*

Type IV: Shallow vestibule and scarred periosteum

Indication

In the etiology of this type of defect, there is either a severe vertical ridge deficiency or a shallow to moderate vertical defect with previous failed regenerative attempts that have translocated the MGJ and scarred the periosteum. Bone graft particles, metal particles, or collagen membranes that resorbed into the periosteum may result in a thickened, inflexible, stone-like periosteum.

Technical note

This type of defect is considered the most difficult. It is possible to perform a free soft tissue graft for vestibular deepening in the shallow Type IV defect and transform it to a Type III defect to continue as a Type III defect. However, in severe vertical defect cases, the treatment should be performed as follows. The papilla shift technique is combined with an extended remote flap elevation and periosteoplasty/periosteal excision. In extreme cases, the internal

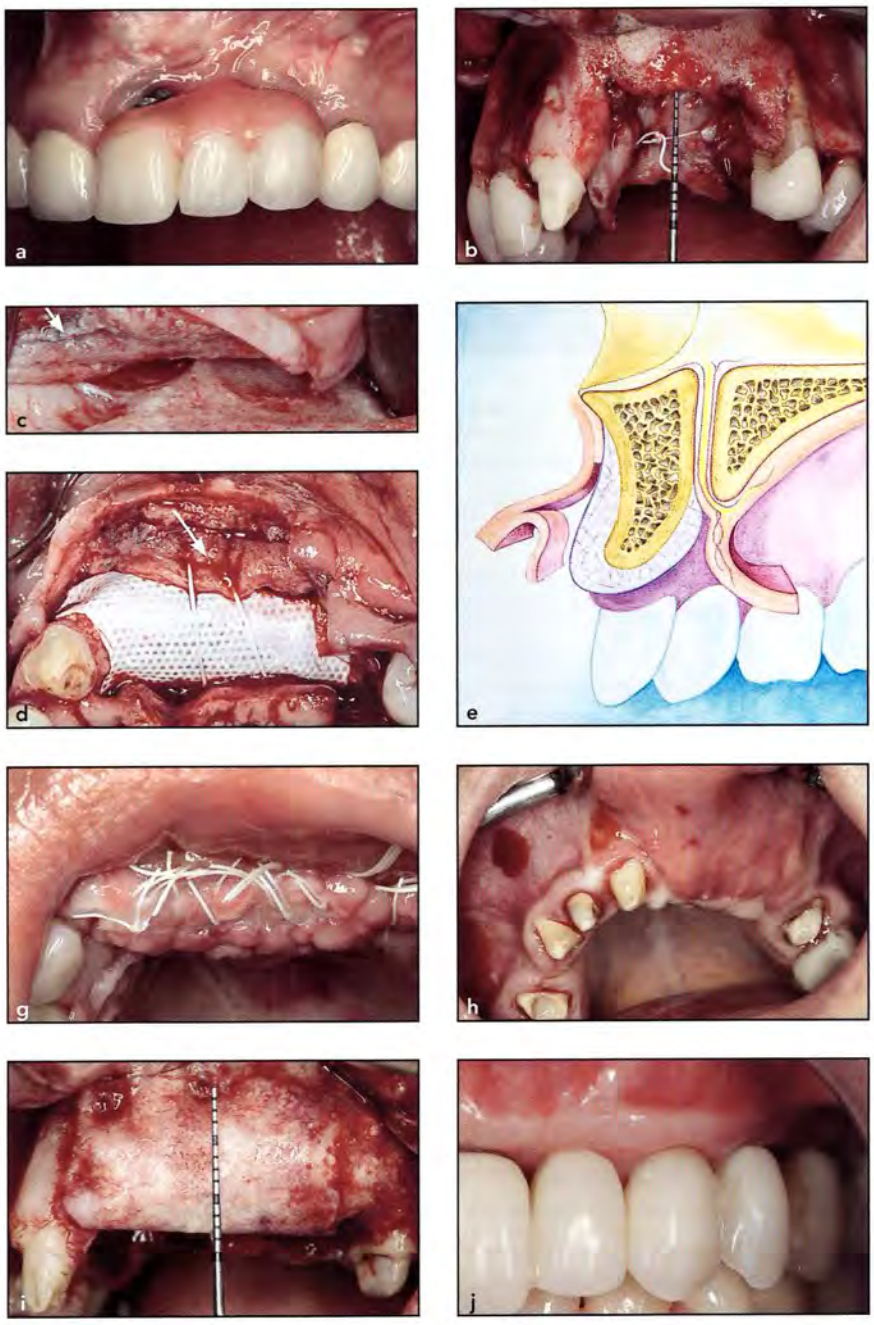

Fig 4 Type IV: *Shallow vestibule and scarred periosteum.* (a) *Labial view of failing implants due to severe peri-implantitis.* (b) *Severe vertical defect with moderate horizontal component.* (c) *Scarred periosteum. The thickened periosteum contains graft and embedded metal particles* (arrow). (d) *Periosteoplasty was performed. Horizontal mattress suture is positioned above the undermined zone of the periosteum (see arrow).* (e) *Schematic drawing demonstrating periosteoplasty.* (f) *A combination of periosteoplasty, suborbicularis preparation, and papilla shift was performed to allow tension-free flap closure. Double layer suturing was used to achieve primary wound closure.* (g) *Soft tissue healing 2 weeks following surgery.* (h) *Occlusal view of uneventful healing after 9 months of bone grafting.* (i) *Successful guided bone regeneration by means of vertical ridge augmentation.* (j) *Optimum esthetic and functional outcomes after provisional restoration phase was completed.* (Figs 4b and 4i were reprinted from Urban et al[29] with permission from Quintessence Publishing Co Inc.)

preparation of the flap under the periosteum can be combined with suborbicularis preparation. This way soft tissue can be gained from the coronal as well as the lateral region. In general, in a Type IV defect the surgical management of Type II and III defects is combined (Figs 4 and 5).

Discussion

Primary wound closure is regarded as the most critical factor for successful healing of GBR, especially in VRA.[9,14] If dehiscence occurs, a drastic reduction in bone gain may be expected.[15] Consequently, proper soft tissue management and a tension-free flap with adequate vascular supply are prerequisites to achieve the desired clinical outcomes.[16–18] Key to achieving wound closure is not only the clinician's ability but also good soft tissue quality and quantity. Soft tissue may shift after

Fig 5 (a) *Radiographic image of implants after 2 years of function with Type IV vertical deficiency. By applying this approach, peri-implant bone gain is maintained, providing optimum esthetic outcomes.* (b) *Frontal view of provisional restoration in function with implant-supported fixed prosthesis. Natural appearance is achieved in the peri-implant tissues by applying this approach.*

closure, often resulting in a severe apical translocation of the MGJ and loss of vestibule and keratinized mucosa. This may lead to esthetic and phonetic problems as well as higher peri-implant plaque accumulation, inflammation, and attachment loss.[19,20] A variety of techniques have been suggested to attain tension-free flap closure.[21–24] However, the authors are not aware of a proposed treatment guideline that considers the anatomical characteristics and changes in soft tissue characteristics that may be present in some patients due to previous attempts at VRA or severe horizontal and/or vertical atrophy. As such, a classification has been proposed to assist clinicians in successfully confronting these challenging scenarios.

Generally speaking, flap advancement relies on elastic fiber detachment (periosteal scoring). In combination with vertical incisions, it is regarded as the basis for tension-free closure. Park et al demonstrated that in trapezoidal full-thickness flap, length could be extended up to 5.5 ± 1.5 mm coronally (171%) regardless of gender and surgical site with adequate periosteal scoring.[16] As previously mentioned, the purpose of the advancement is not only to cover the graft but also to achieve tension-free closure. Burkhardt and Lang showed that higher tension forces (> 0.1 N) significantly increased the likelihood of dehiscence.[25] Furthermore, gingival thickness appears to positively influence wound stability.[26,27] The double-layer suture technique is intended to overcome this problem. The reason vestibular depth is increased via free gingival grafting in shallow vertical Type II and IV defects is to achieve greater tissue quantity and quality for easier and more predictable soft tissue closure.[28] Additionally, tension-free closure relies on manipulation and repositioning of the musculature when it impedes proper coronal advancement. This is of critical importance in Type II and IV defects, where severe or shallow to moderate (up to 6 mm) vertical ridge deficiency is combined with a horizontal component. In such cases, a suborbicularis preparation is often needed to release tension from musculature attachment. Likewise, the presence of scarring on the periosteum limits soft tissue advancement. Accordingly, higher sensitivity to the overall VRA flap management is required. This is particularly difficult in Type IV defects due to the severe vertical atrophy with lack of KM. Last but not least, the double-layer suturing method plays a determinant role in flap stability. Hence, the appropriate material and technique must be selected to avoid dehiscence. It was observed that in sutures thicker than 3.0, tearing occurs at an average of 13.4 N, and in sutures 5.0 or thinner, breakage happens at a mean applied force of 3.6 N.[27] Thicker sutures may safely secure flap advancement; nonetheless, passive adaptation is required to avoid excessive tension that might jeopardize tissue integrity.[17]

The goal of this classification is to assist clinicians to achieve tension-free flap closure during VRA for the anterior atrophic maxilla. One of the limitations of the classification is the lack of clinical data to validate the proposed guidelines and suggestions. Hence, future clinical trials with larger sample size are needed to validate these recommendations.

Conclusions

Tension-free closure is a requisite for achieving successful VRA in the anterior atrophic maxilla. Several anatomical characteristics have to

be evaluated prior to surgery. Before designing a flap, clinicians must consider the depth of the vestibule, periosteum quality/integrity, and anatomical characteristics to achieve tension-free primary closure and ensure a good clinical outcome. An in-depth knowledge of the surgical solution of vertical ridge defects in the anterior maxilla is provided herein.

Acknowledgments

Dr Urban and Dr Wang received honoraria for lecturing from Osteogenics Biomedical. In addition, Dr Urban, Dr Myron Nevins, and Dr Marc Nevins received honoraria for lecturing from Geistlich Pharma. This paper was partially supported by the University of Michigan Periodontal Graduate Student Research Fund. The authors reported no conflicts of interest related to this study.

References

1. Rocchietta I, Fontana F, Simion M. Clinical outcomes of vertical bone augmentation to enable dental implant placement: A systematic review. J Clin Periodontol 2008;35:203–215.
2. Rocchietta I, Simion M, Hoffmann M, Trisciuoglio D, Benigni M, Dahlin C. Vertical bone augmentation with an autogenous block or particles in combination with guided bone regeneration: A clinical and histological preliminary study in humans. Clin Implant Dent Relat Res 2016;18:19–29.
3. Simion M, Dahlin C, Rocchietta I, Stavropoulos A, Sanchez R, Karring T. Vertical ridge augmentation with guided bone regeneration in association with dental implants: An experimental study in dogs. Clin Oral Implants Res 2007;18:86–94.
4. Tonetti MS, Hämmerle CH. Advances in bone augmentation to enable dental implant placement: Consensus Report of the Sixth European Workshop on Periodontology. J Clin Periodontol 2008;35: 168–172.
5. Urban I, Caplanis N, Lozada JL. Simultaneous vertical guided bone regeneration and guided tissue regeneration in the posterior maxilla using recombinant human platelet-derived growth factor: A case report. J Oral Implantol 2009;35:251–256.
6. Urban IA, Jovanovic SA, Lozada JL. Vertical ridge augmentation using guided bone regeneration (GBR) in three clinical scenarios prior to implant placement: A retrospective study of 35 patients 12 to 72 months after loading. Int J Oral Maxillofac Implants 2009;24:502–510.
7. Merli M, Moscatelli M, Mariotti G, Rotundo R, Bernardelli F, Nieri M. Bone level variation after vertical ridge augmentation: Resorbable barriers versus titanium-reinforced barriers. A 6-year double-blind randomized clinical trial. Int J Oral Maxillofac Implants 2014;29:905–913.
8. Urban IA, Monje A, Wang HL. Vertical ridge augmentation and soft tissue correction for the anterior atrophic maxillae: A case series. Int J Periodontics Restorative Dent (in press).
9. Wang HL, Boyapati L. "PASS" principles for predictable bone regeneration. Implant Dent 2006;15:8–17.
10. Tonetti MS, Pini-Prato G, Cortellini P. Periodontal regeneration of human intrabony defects. IV. Determinants of healing response. J Periodontol 1993; 64:934–940.
11. Pini-Prato G, Nieri M, Pagliaro U, et al. Surgical treatment of single gingival recessions: Clinical guidelines. Eur J Oral Implantol 2014;7:9–43.
12. Tinti C, Parma-Benfenati S, Polizzi G. Vertical ridge augmentation: What is the limit? Int J Periodontics Restorative Dent 1996;16:220–229.
13. Triaca A, Minoretti R, Merli M, Merz B. Periosteoplasty for soft tissue closure and augmentation in preprosthetic surgery: A surgical report. Int J Oral Maxillofac Implants 2001;16:851–856.
14. Leong DJ, Oh TJ, Benavides E, Al-Hezaimi K, Misch CE, Wang HL. Comparison between sandwich bone augmentation and allogenic block graft for vertical ridge augmentation in the posterior mandible. Implant Dent 2015;24:4–12.
15. Machtei EE. The effect of membrane exposure on the outcome of regenerative procedures in humans: A meta-analysis. J Periodontol 2001;72:512–516.
16. Park JC, Kim CS, Choi SH, Cho KS, Chai JK, Jung UW. Flap extension attained by vertical and periosteal-releasing incisions: A prospective cohort study. Clin Oral Implants Res 2012;23:993–998.
17. Burkhardt R, Lang NP. Fundamental principles in periodontal plastic surgery and mucosal augmentation–a narrative review. J Clin Periodontol 2014;41:S98–S107.
18. Sanz M, Simion M. Surgical techniques on periodontal plastic surgery and soft tissue regeneration: Consensus report of Group 3 of the 10th European Workshop on Periodontology. J Clin Periodontol 2014;41:S92–S97.
19. Lin GH, Chan HL, Wang HL. The significance of keratinized mucosa on implant health: A systematic review. J Periodontol 2013;84:1755–1767.
20. Gobbato L, Avila-Ortiz G, Sohrabi K, Wang CW, Karimbux N. The effect of keratinized mucosa width on peri-implant health: A systematic review. Int J Oral Maxillofac Implants 2013;28: 1536–1545.
21. Tinti C, Parma-Benfenati S. Coronally positioned palatal sliding flap. Int J Periodontics Restorative Dent 1995;15: 298–310.
22. Goldstein M, Boyan BD, Schwartz Z. The palatal advanced flap: A pedicle flap for primary coverage of immediately placed implants. Clin Oral Implants Res 2002;13:644–650.
23. Becker W, Becker BE. Guided tissue regeneration for implants placed into extraction sockets and for implant dehiscences: Surgical techniques and case report. Int J Periodontics Restorative Dent 1990;10:376–391.
24. Hürzeler MB, Weng D. Functional and esthetic outcome enhancement of periodontal surgery by application of plastic surgery principles. Int J Periodontics Restorative Dent 1999;19:36–43.
25. Burkhardt R, Lang NP. Role of flap tension in primary wound closure of mucoperiosteal flaps: A prospective cohort study. Clin Oral Implants Res 2010;21:50–54.
26. Hwang D, Wang HL. Flap thickness as a predictor of root coverage: A systematic review. J Periodontol 2006;77:1625–1634.
27. Burkhardt R, Preiss A, Joss A, Lang NP. Influence of suture tension to the tearing characteristics of the soft tissues: An in vitro experiment. Clin Oral Implant Res 2008;19:314–319.
28. Thoma DS, Benić GI, Zwahlen M, Hämmerle CH, Jung RE. A systematic review assessing soft tissue augmentation techniques. Clin Oral Implants Res 2009;20:s146–s165.
29. Urban IA, Lozada JL, Jovanovic SA, Nagursky H, Nagy K. Vertical ridge augmentation with titanium-reinforced, dense-PTFE membranes and a combination of particulated autogenous bone and anorganic bovine bone-derived mineral: A prospective case series in 19 patients. Int J Oral Maxillofac Implants 2014;29:185–193.