

# Vertical ridge augmentation procedure in the posterior maxilla by means of a porcine pericardium collagen membrane and a porcine particulate xenograft mixed with autogenous particulate bone graft: a case report

Author: Dr Fabrizio Belleggia, DDS Specialized in Oral Surgery, Private Practice, Rome, Italy  
fabriziobelleggia@virgilio.it

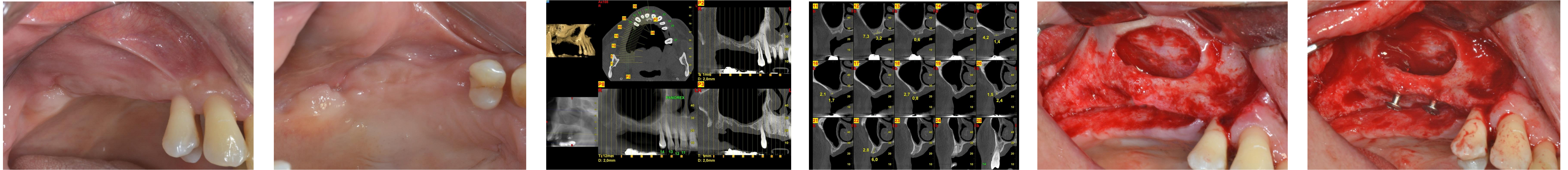


## Objectives:

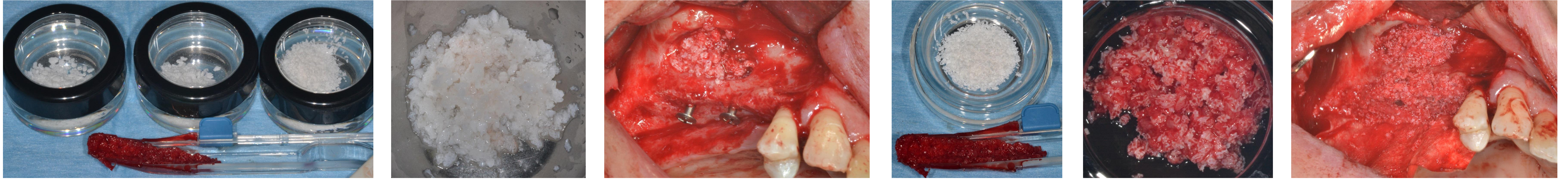
Vertical ridge augmentation by means of resorbable membranes is not a well documented and predictable technique to correct vertical crestal bone defects, since the first mebranes had a rather rapid resorption time and were not stiff enough to resist collapse into the underlying defect. The aim of this study was to evaluate the use of a new pocine pericardium collagen membrane and a new porcine xenograft in the treatment of a distal extension vertical ridge deficiency.

## Methods:

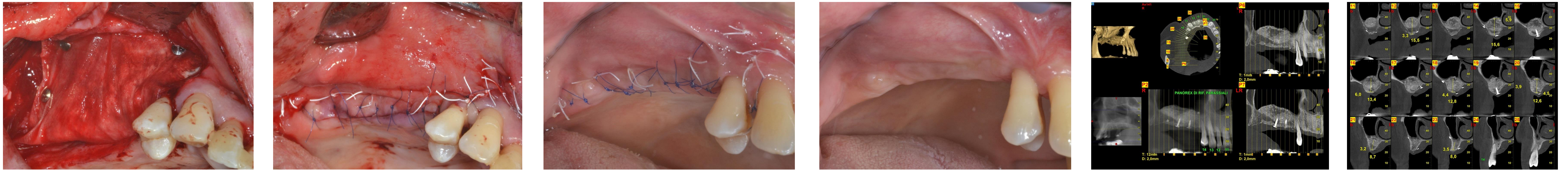
A patient came to the attention of the author requiring an implant rehabilitation of the posterior right maxilla. CT scans revealed a crestal bone height less than 1 mm in most of the ridge. A simultaneous lateral sinus lift procedure was performed, harvesting autogenous bone graft with a bone scraper from the buccal bone wall, where was performed the access. After sinus membrane elevation, the sinus was grafted with a 100% large particle size porcine xenograft (Zcore, Osteogenics Biomedical), two tenting screws (Pro-fix, Osteogenics Biomedical) were inserted perpendicular to the crest, leaving them outside the ridge for about 3 mm. A mixture, in a 1:1 ratio, of autogenous particulate bone, harvested during the lateral sinus entrance preparation, and small particle size porcine xenograft (Zcore, Osteogenics Biomedical)was applied to correct the ridge's vertical defect. The graft was covered by a porcine pericardium collagen membrane (Vitala, Osteogenics Biomedical), stabilized with titanium pins both on the palatal and buccal side. The buccal flap was properly released to move coronally without tension, and a double layer suture allowed a tension-free closure. Healing was uneventful, and two weeks later the patient was scheduled for suture removal.



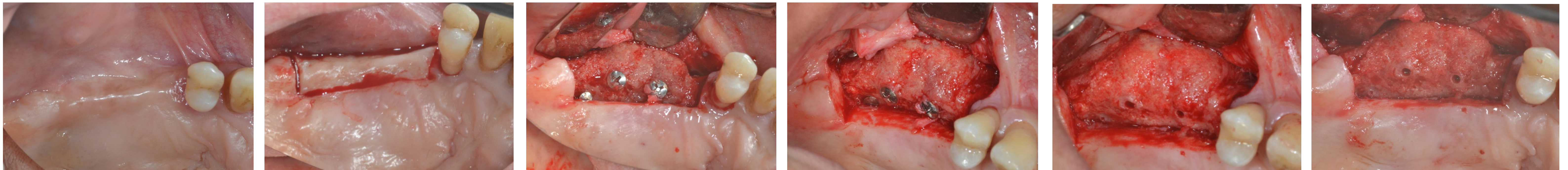
Vertical and horizontal bone defect in the upper right premolar/molar area . A sinus lift with lateral approach was performed and 2 Pro-fix tenting screws were inserted to withstand the membrane collapse.



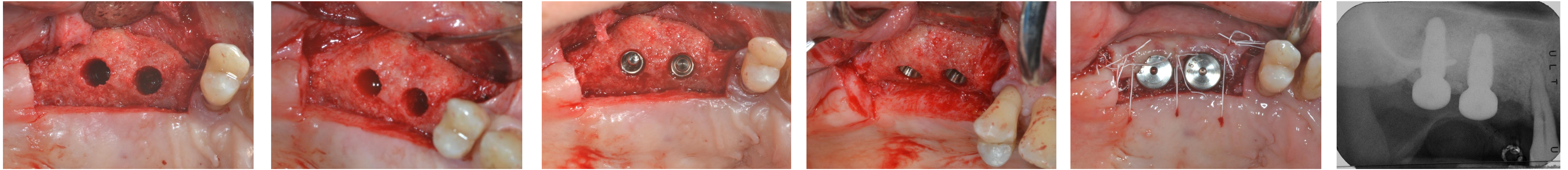
100% large size Zcore particles were used to graft the sinus, while the cortical autogenous bone harvested with a Safescraper Twist was mixed to 1 cc small size Zcore particles to graft the ridge defect.



A 30x40 Vitala membrane was stabilized with pins to cover the bone graft. Healing was uneventful . The post-op Cone Beam Computed Tomography revealed the amount of bone augmentation obtained.



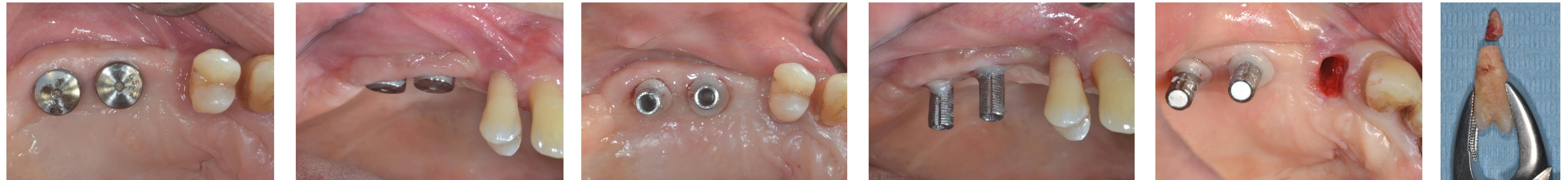
Re-entry was scheduled 10 months after the GBR. Bone was augmented either in an horizontal and vertical direction, up to the heads of the tenting screws, that were left exposed for about 3 mm from the ridge.



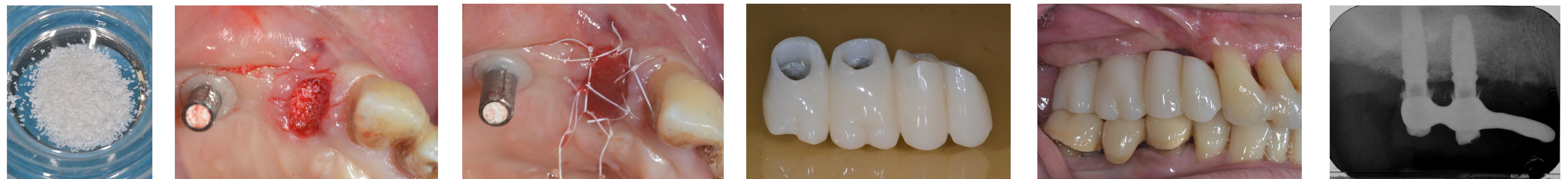2 Cowellmedi Inno Sub implants were inserted in the first and second molar position, and healing abutments were connected. The flap was repositioned in a buccal direction for keratinied mucosa augmentation.

## Results:

A new CT scan was requested 6 months after the augmentation procedure. The exam revealed a mean of 13 mm of vertical bone height (range 8,7-15,6), with a vertical extension above the sinus of about 3 to 4 mm. Re-entry was scheduled 10 months after bone augmentation. The site healed uneventfully during all this period. Crestal incision was shifted in a more palatal position in order to move the band of keratinized tissue buccally. The regenerated tissue appeared very mature and compact, while the two tenting screws, left exposed 3 mm above the ridge, were completely surrounded by regenerated bone up to their heads. The presence of xenograft particles was not very evident, sign of an advanced bone remodeling. This could be due to the interconnecting macroscopic and microscopic porous structure of the graft material that supports the formation and ingrowth of new bone. Hyper porosity of porcine cancellous matrix and intra-particle space (88% to 95% void space) reduced bulk density of the graft, allowing greater empty space for new bone growth . After tenting screws and titanium pins removal, implant bed preparations were performed. Two Inno Sub implants (Cowellmedi) were inserted 1 mm under the crest, as per the manufacturer's surgical protocol, in the first and second molar position. Healing abutments were immediately connected for a trans-mucosal healing. Three months later implants were prosthetically loaded.



Three months after implant insertion, two provisional abutments were connected to the implants and the first premolar, affected by severe periodontal disease and mobility, was extracted.



A socket preservation was performed with Zcore , covered by a resorbable collagen matrix sutured over the graft. A provisional prosthesis with mesial cantilever was delivered while waiting to place an implant.

## Conclusions:

Vertical ridge augmentation was obtained with a guided bone regeneration procedure, in combination with a lateral sinus lift, by means of a resorbable porcine pericardium collagen membrane and a graft composed by autogenous particulate cortical bone mixed with a porcine particulate xenograft. Membrane support is a crucial factor when it is used to correct defects outside the bone envelope, especially if it is a resorbable one. The use of two tenting screws, together with the presence of the grafting material, prevented the membrane from collapsing on the defect, so as to obtain 3 to 4 mm of vertical ridge increase, outside the sinus area. Membrane stabilization with titanium pins was a crucial factor too, since graft stability was granted by the membrane appropriately pulled and immobilized above the bone graft that filled the defect.