

## NEW GENERATION PTFE-MEMBRANES

# Non-resorbable membranes

In the eighties and nineties various regenerative materials have been introduced in the fields of periodontics and implantology. Many of these materials make use of the principle of guided tissue regeneration (GTR), which also includes guided bone regeneration (GBR). The then used non-resorbable membranes could lead to good results. A considerable disadvantage, however, was that during exposure of a non-resorbable membrane infections often arose and so this led to a (partial) failure. The introduction of a “new” non-resorbable membrane will eliminate this disadvantage. Melle Vroom and Lodewijk Gründemann give a report below of their experiences regarding the use of these membranes.

**T**he principle of the GTR/GBR roughly means that due to sealing off a cavity with the help of a regenerative material the epithelial cells and connective tissue cells can be shut out and bone regeneration is made possible from the inside out. This gives more time to the process of bone regeneration. One of these regenerative materials is the material which has as its base polytetrafluoroethylene (PTFE), which has various applications in medical disciplines such as in cardiovascular surgery where it has been used for over thirty years. Within the fields of periodontics and implantology a form of PTFE which was treated by means of heating and applying pressures, was introduced in the eighties. This resulted in an expanded form (e-PTFE).

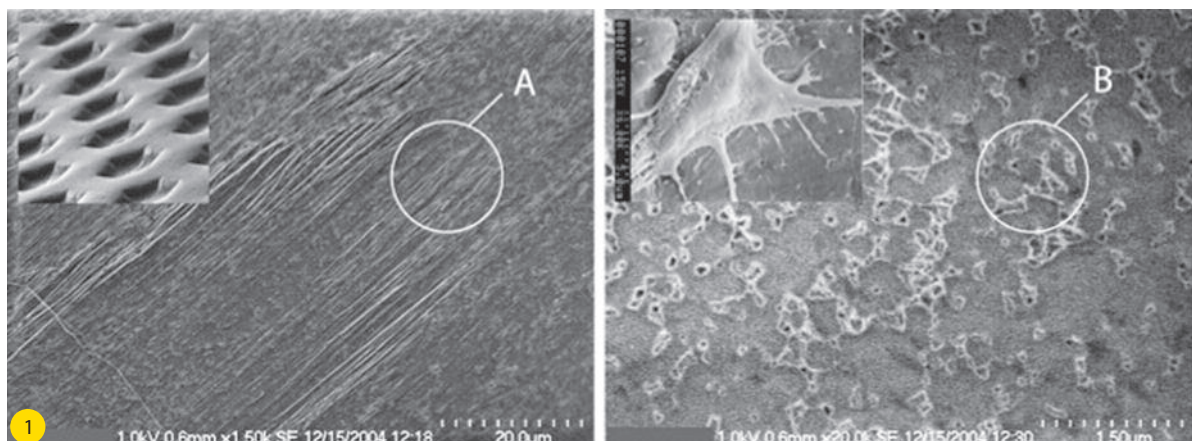
This form, with or without titanium reinforcement, was manufac-

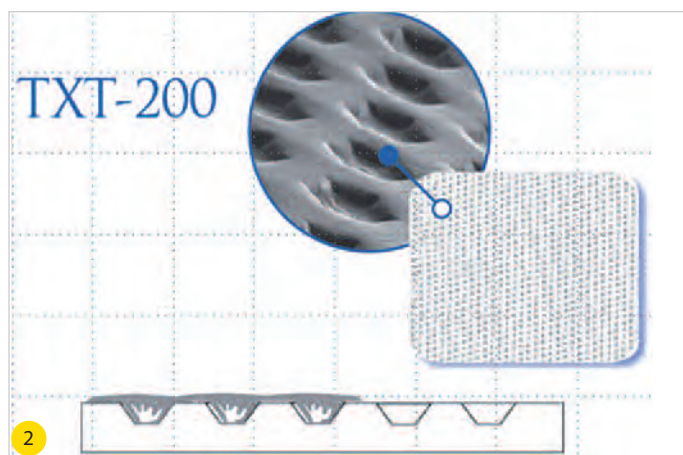
**M.G. Vroom MSc** qualified as a dentist (ACTA = Academic Centre for Dentistry Amsterdam) in 1994 and as a periodontist (ACTA) in 1998.

**L.J.M.M. Gründemann MSc** qualified as a dentist (State University Utrecht) in 1988 and as a periodontist (ACTA) in 1998. Both authors are working as periodontists (NVvP = Dutch Union of Periodontists) and implantologists (NVOI = Dutch Union for Oral Implantology) in private practice the Periodontal Practice Friesland.

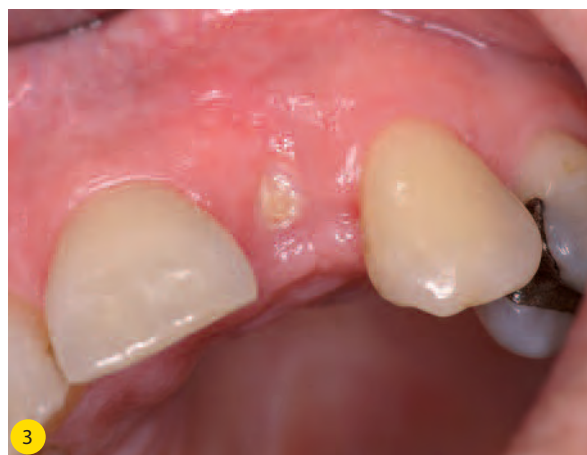tured by the Gore company and has gained a lot of renown within the field of dentistry. Various studies have shown that the use of this material can lead to good (sometimes even spectacular) results.<sup>1</sup>

**Fig. 1** EM-image of the d-PTFE-membrane. The left figure shows an enlargement of the surface at point A. The right figure shows the fibroblasts that attach to the d-PTFE membrane. (Photographs are used by courtesy of Osteogenics Biomedical, Inc.)





**Fig. 2** Schematic image of the modification of the membrane surface (Regentex). Small indentations allow ingrowth of tissue. (Photographs are used by courtesy of Osteogenics Biomedical, Inc.)



**Fig. 2** A non-closed d-PTFE membrane four weeks in the mouth. The membrane was placed directly after extraction of tooth #10.

An important proviso to achieve these results is that after applying an e-PTFE membrane the tissues in the regenerative area remain primarily closed off. This is awkward in larger size bone augmentations because there is not sufficient tissue to cover the extension of the bone. By applying relaxing incisions in many cases the tissues can be stretched more in order to obtain primary closure. The applied suturing techniques are of essential importance in keeping the edges of the wound firmly in position and in maintaining primary closure.

### Exposure of e-PTFE membrane

In case exposure does occur (in approx. 30-40% of the cases) then this will nearly always have a very unfavourable impact on the obtained regeneration rate. This can result in a regeneration rate as low as 0-60%.<sup>2,3</sup> The cause for this is the open structure of an e-PTFE membrane: in case of an exposure, bacteria from the oral cavity will penetrate the e-PTFE membrane and migrate into the regeneration area. This results in the emergence of bacterial infections often accompanied by suppuration.

The association of non-resorbable membranes with exposures that often led to failure has given the e-PTFE membrane a bad reputation among many clinicians. This has resulted into much more attention being paid to the development and applications of resorbable membranes which do not directly lead to failure in case of exposure. Another factor is that in the use of non-resorbable materials an additional raising of the mucoperiosteal flap is required.

Logically, this has led to the widespread application of resorbable materials and the non-resorbable membranes have been pushed into the background and some versions are even no longer available.

However, comparative studies have shown that the use of e-PTFE membranes show better results than the use of resorbable membranes.<sup>1</sup> That is why the e-PTFE is hailed in many regenerative studies as the "golden standard".

### The d-PTFE membrane

Some time ago, an adapted e-PTFE membrane has already been developed. In this process the PTFE is treated without an application of pressures which caused a dense-PTFE (d-PTFE) to emerge. The great advantage of this is that the surface of this membrane has a less open structure which will not allow bacteria and bacterial products to penetrate it (figure 1). In the right half of figure 1 we can see how fibroblasts attach to the d-PTFE membrane. The

d-PTFE membrane was marketed by the Osteogenics company under the brand name Cytoplast™ (with or without titanium reinforcement) in 1998.

The company also added another modification in the surface of the d-PTFE membrane (figure 2). In the surface situated against the inside of the flap tiny indentations have been made. These indentations allow partial ingrowth of tissue. This causes a reinforced connection between flap and membrane which, in case of exposure, limits the epithelial ingrowth and prevents the migration of bacteria alongside the membrane. It is remarkable that this d-PTFE membrane was virtually ignored in the Netherlands as far as we can tell, although very good results have been achieved by its use. A possible explanation for this is the negative association many clinicians have had in the past due to experiences with non-resorbable (e-PTFE) membranes with re-entries, infections and failures.

Studies have shown that the d-PTFE membrane achieves comparable results to the e-PTFE membrane and is easier to remove.<sup>4</sup> The latter is the case because the connection of the d-PTFE membrane to the inside of the flap and the regenerative tissue can be more easily cut by the use of dental instruments. In the application of d-PTFE membranes, it is of course most desirable to have no exposure of the membrane and/or the tissues in the augmentation area. That this is not so easy is shown in various studies that demonstrate an occurrence rate of exposure of 20% to 30% during GTR treatments. So the treatment of soft tissues is of essential importance. That is why a review indicates that GTR/GBR procedures are not simple and require a high level of expertise and skill on the part of the practitioner.<sup>1</sup>

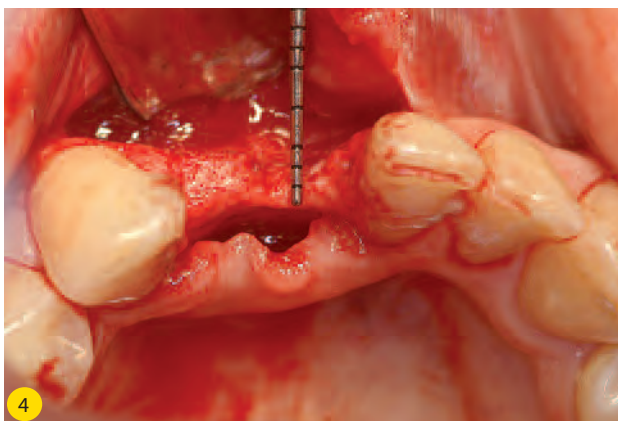
However, if an exposure occurs with the use of a d-PTFE membrane, this will not automatically lead to infections and failure if a well-considered protocol is followed.

### The d-PTFE membrane in practice.

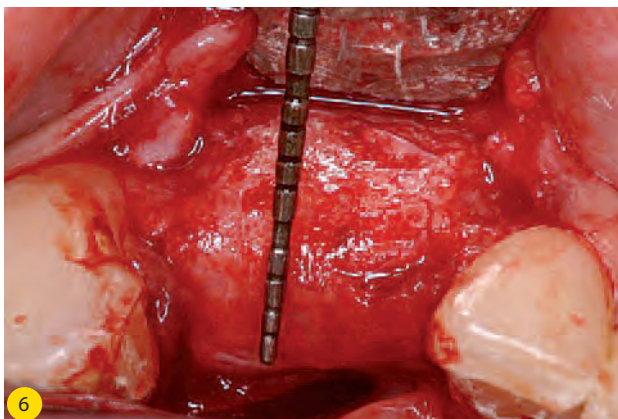
Various approaches are possible in practice for the use of d-PTFE membranes. The use directly after an extraction is an indication which we will further discuss in another paper in this magazine. In this application we can easily experience how undisturbed the clinical picture is if a d-PTFE membrane does have an open connection to the oral cavity (figure 3).

In our practice we have been using the d-PTFE membranes for a considerable period with so far very satisfactory results. We will

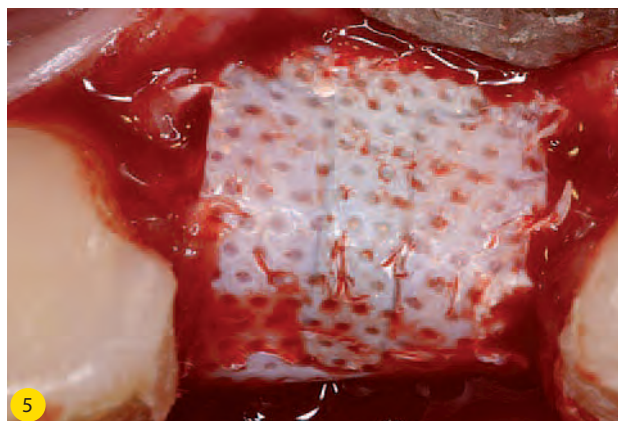




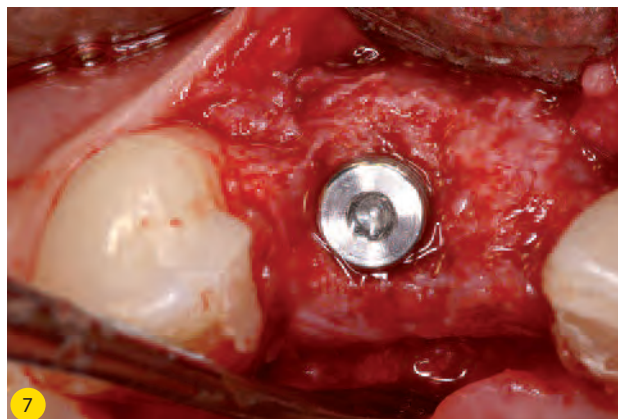
**Fig. 4** The area of #23, 24 before the bone augmentation. The top of the alveolar process shows a width of 1-2 mm.



**Fig. 6** After removal of the d-PTFE membrane the increase of bone width is clearly visible. Compare to figure 4.



**Fig. 5** Clinical picture before the removal of the d-PTFE membrane five months after placement.



**Fig. 7** Placement of an implant on position #23 as a base of the future replacement of #23 and 24.

discuss some of these cases in combination with clinical pictures.

#### Case 1 (figures 4-7)

The first case concerns a 23-year old woman who was referred to us for an implant in the area of #23 and 24. Periodontically there are no specific problems. The clinical situation (figure 4) of the lower front teeth shows that the bone width is much too limited at the top of the alveolar process, i.e. 1-2 mm. We decided to perform a bone augmentation in the area of #23, 24 with the use of a d-PTFE membrane with titanium reinforcement. As filler underneath the membrane, we made use of an allogenic bone material to gain more stability and to support the regeneration process.<sup>5,6,7</sup> The healing proceeded without any problems and the tissues remained primarily closed. After five months we removed the d-PTFE membrane. A bone augmentation of 6-7 mm was the result (figures 5-6). Placing an implant was now relatively easy (figure 7). During the drilling out, a very good hardness was observable in the regenerative tissue. In comparing clinical pictures 5 and 6 it is clearly visible that the regenerative tissue exactly follows the outline as dictated by the d-PTFE membrane. That shows the importance of deliberately pre-shaping the membrane.

#### Case 2 (figures 8-11)

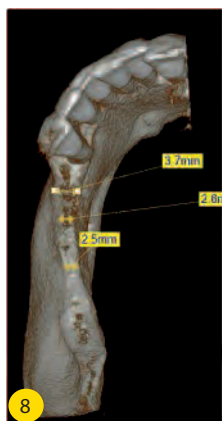The second case concerns a 58-year old woman, who wished for a fixed prosthesis in the third quadrant. After periodontal treatment she was in the follow-up care stage and showed a stable, healthy periodontium. The 3-D image generated by a CB-CT scan (figure 8) of the third quadrant, however, showed an alveolar process whose width was too limited at the top. We decided to perform a bone augmentation in the area of #18-21 using a titanium reinforced

d-PTFE membrane with the object of placing implants later. The membrane was fixed with a membrane fixation screw and underneath the membrane we applied allogenic bone material. Healing proceeded without any complications and the tissues remained closed. After six months we removed the d-PTFE membrane and the fixation screw. A bone augmentation of approx. 7 mm was the result of regeneration (figures 9-10). The implants could then be placed (figure 11). In this case hard regeneration tissue was also shown to be present during drilling out. Figure 11 shows that bone augmentation in the area of #21 is possible even beyond the physiological limits of the alveolar process. This was also proven in an experimental study.<sup>8,9</sup>

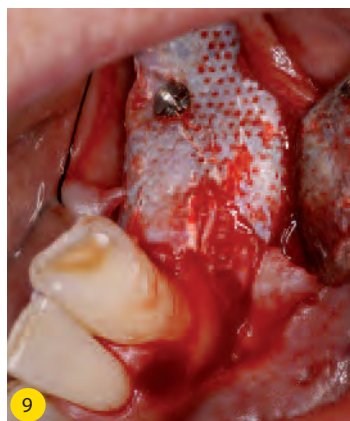
Fixing the membrane with the (Pro-fix™) membrane fixation screw enabled us to make slight shape adaptations to the membrane even after placement without moving the membrane. The fixation screw prevents/limits micro movements of the membrane from having a negative impact on the bone regeneration. Because GTR treatments as described above are a sort of oral orthopedics in our opinion, they require proper surgical treatment/techniques. Especially in the light of sterile/hygienic surgical procedures.

#### d-PTFE regeneration limits (vertical/horizontal)

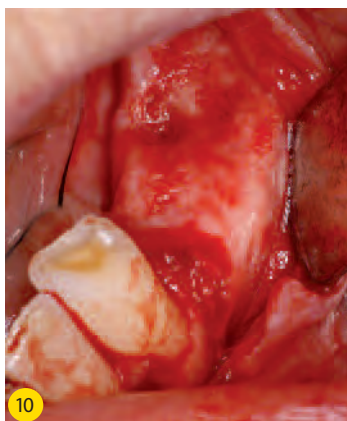In studies horizontal extensions of 3.1 mm to 7.1 mm have been reported.<sup>2, 10, 11</sup> The great challenge is to realize the vertical bone augmentation. In a vertical sense increases of 4-7 mm supracrestal bone augmentation are feasible according to some studies.<sup>12, 13</sup> In this case the challenge is even greater in dealing with the soft tissues in such a way that primary closure is feasible and stable.



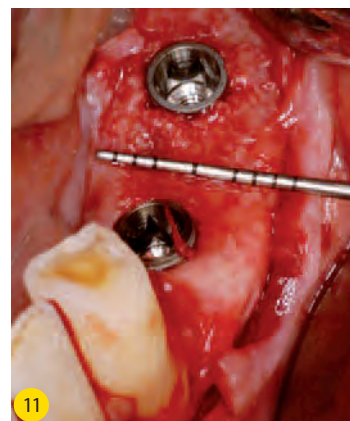
**Fig. 8** The 3D-image (CB-CT scan) shows a limited bone width.



**Fig. 9** Clinical picture before the removal six months after placing the d-PTFE membrane with titanium reinforcement and a membrane fixation screw.



**Fig. 10** Picture of the regenerative tissue directly after removal of the d-PTFE membrane. The indentation where the fixation screw was located is visible in the coronal area of #20.

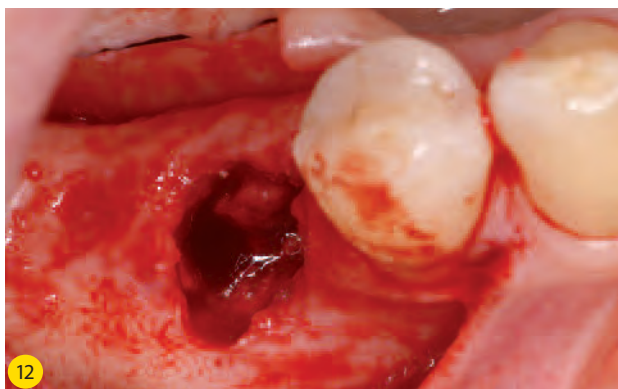


**Fig. 11** Placing implants #19 and 21. The increased bone width is clearly visible. Compare to figure 8.

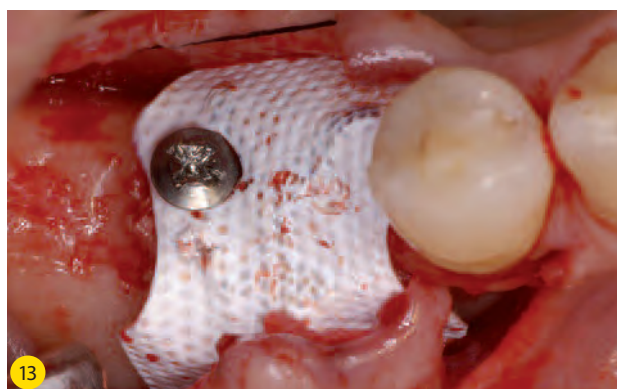
## Clinical treatment exposures

We have also observed the occurrence of exposures in some cases of bone augmentation in our practice. Experience teaches us that an exposure can already be observed during the removal of the sutures, but sometimes only after a couple of months. That is why the patient receives instructions to check the augmentation area carefully at least twice a week and in case of a visible membrane ('a spot with the colour of white paper') to get in touch with the practice immediately. It is also good to let the patient know that an exposure not by any means (directly) means that the procedure has failed. In addition, it might be sensible to make sure that the referring dentist doesn't assume the exposure is exposed bone and

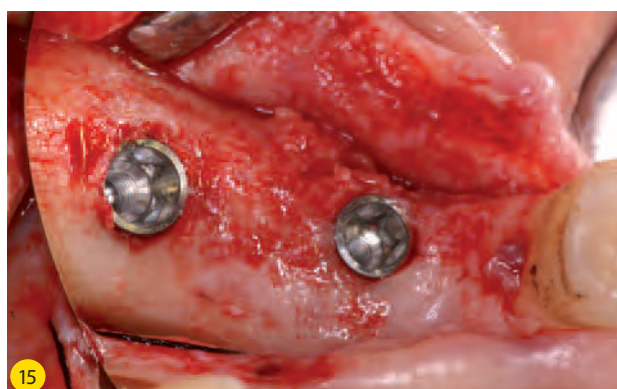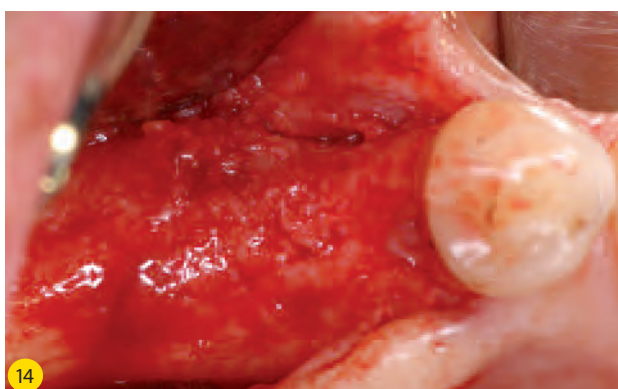
mistakenly treats it accordingly. The exact time the exposure occurs is of clinical importance. Histological studies have shown that the foundation for bone generation is laid after four weeks.<sup>14, 15</sup> We speak of an osteoid matrix then. It is crucial, therefore, to prevent any inflammatory reactions during the first four weeks even in case of an exposure. This is perfectly possible while using a d-PTFE membrane. But if, in case of an exposure, the edge of the membrane is also exposed, there is a definite point of entry. Early removal of the membrane is then indicated. If the underlying regenerative tissue has not become involved in the inflammation process, it is still possible to obtain regeneration even in such a situation.



**Fig. 12** The #29 area before the bone augmentation.



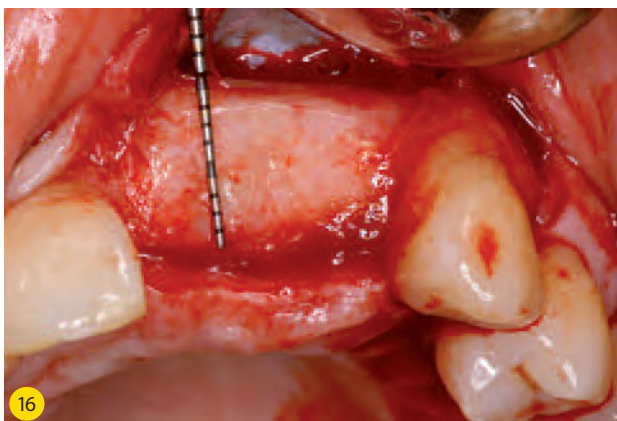**Fig. 13** A d-PTFE membrane has been placed and fixed with a membrane fixation screw.



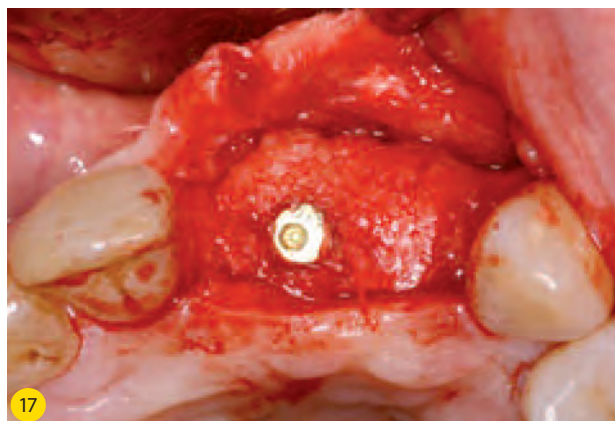
**Fig. 14** Picture of regenerative tissue four months after placement and two months after removal of the d-PTFE membrane.

**Fig. 15** Placing an implant in the area of #29 is perfectly possible now.





**Fig. 16** The regenerative tissue immediately after removal of the d-PTFE membrane. The membrane was removed earlier than planned on account of the presence of a fistula. The implant in position #9, that had been placed together with the d-PTFE membrane, has been overgrown with hard regenerative tissue.



**Fig. 17** Second-stage treatment three months after removal of the membrane. The implant becomes visible after first removing hard regenerated tissue by means of rotary instruments.

### Case 3 (figures 12-15)

In the third case, more than two months after placing a d-PTFE membrane a local exposure emerged in the area of #29 (figures 12-13). For the 57-year old patient, the plan was to place two implants in the fourth quadrant. The area to be augmented showed a defect in the beginning in which the vestibular wall was lacking (figure 12). Here we removed the d-PTFE membrane after diagnosing the exposure. After a two-month healing period we placed the implants. Figure 14 shows that the surface of the regenerative tissue does not appear as smooth as in the previously shown case, where the membrane remained in place for a longer period without exposure. The bone situation still enabled us to place the implants (figure 15).

### Complications

One complication we have occasionally observed is the emergence of a swelling in the tissues 2-3 months after placing the membranes. Sometimes accompanied by fistula formation. If in such a case the membrane is removed, the swelling will quickly fade. It is remarkable that we have observed that the augmentation process in such a case will still provide a good result. One example of this is case 4, the treatment of a 44-year old patient who was provided with an implant in the area of #9 directly after removing #9 and 10. We combined this with bone augmentation (d-PTFE membrane and allogenic bone material). After 2 months a fistula was formed and we removed the membrane. The clinical picture immediately after the removal of the membrane still showed a lot

of hard regenerative tissue that had even grown over the implant (figure 16). After three months the second-stage treatment was performed, in which the implant was sought out by removing bone (figure 17).

### d-PTFE without titanium reinforcement

The application of a d-PTFE membrane without titanium reinforcement is perfectly possible in case of smaller bone augmentations. For example in combination with placing an implant. The membrane in such a case has mainly a protective function and can easily be removed during second-stage treatment. Currently, many clinicians use a resorbable membrane in such cases. But the use of a d-PTFE membrane is much more convenient because these membranes are considerably less expensive than resorbable membranes.

### Conclusion

The d-PTFE membrane is a perfectly useful membrane whose use can lead to very good results. Considering its broad applicability, we think the d-PTFE membrane can become the new standard product and it is often preferable to a resorbable membrane.

*The authors declare they gain no financial benefits from mentioning the products named in this article.*

- 1) Hämmeler, C.H.F. & Jung, R.E. (2003)  
*Bone augmentations by means of barrier membranes. Periodontology* 2000 33, 36-53
- 2) Lang, N.P., Brägger, U., Hämmeler, C.H.F. & Sutter, F. (1994a)  
*Immediate transmucosal implants using the principle of guided tissue regeneration. I. rationale, clinical procedures and 30-month results. Clinical Oral Implants Research* 5, 154-163.
- 3) Lang, N.P., Hämmeler, C.H.F., Brägger, U., Lehman, B. & Nyman, S.R. (1994b)  
*Guided tissue regeneration in jaw bone defects prior to implant placement. Clinical Oral Implants Research* 5, 92-97.
- 4) Ronda, M., Rebaudi, A., Torelli, L. & Stacchi, C. (2013)  
*Expanded vs. dense polytetrafluoro-ethylene membranes in vertical ridge augmentation around dental implants: a prospective randomized controlled clinical trial. Clinical Oral Implants Research* 00, 1-8.
- 5) Buser, D., Ruskin, J., Higginbottom, F., Hartwick, R., Dahlin, C. & Schenk, R.K. (1995b)  
*Osseointegration of titanium implantants in bone regenerated in membrane-protected defects. A histologic study in the canine mandible. International Journal of Oral and Maxillofacial Implants* 10, 666-681.
- 6) Buser, D., Dula, K., Belser, H., Hirt, H.P. & Berthold, H. (1995a)  
*Localized ridge augmentation using guided bone regeneration. II. Surgical procedures in the mandible. International Journal of Periodontics and Restorative Dentistry* 15, 13-29.
- 7) Simion, M., Jovanovic, S.A., Trisi, P., Scarano, A. & Piattelli, A. (1998)  
*Vertical ridge augmentation around dental implants using a membrane technique and autogenous bone or allografts in humans. International Journal of Periodontics and Restorative Dentistry* 18, 9-23.
- 8) Kostopoulos, L. & Karring, T. (1994a)  
*Guided bone regeneration in mandibular defects in rats using a bioresorbable polymer. Clinical Oral Implants Research* 5, 66-74.
- 9) Kostopoulos, L. & Karring, T. (1994b)  
*Augmentation of the rat mandible using the principle of guided tissue regeneration. Clinical Oral Implants Research* 5, 75-82
- 10) Buser, D., Dula, K., Belser, H., Hirt, H.P. & Schenk, R.K. (1996a)  
*Lateral ridge augmentation using autographs and barrier membranes: A clinical study with 40 partially edentulous patients. Journal of Oral and Maxillofacial Surgery* 54, 420-434.
- 11) Buser, D., Dula, K., Lang, N.P. & Nyman, S. (1996b)  
*Long-term stability of osseointegrated implants in bone regenerated with the membrane technique. 5-years results of a prospective study with 12 implants. Clinical Oral Implants Research* 7, 175-183.
- 12) Simion, M., Trisi, P. & Piattelli, A. (1994)  
*Vertical ridge augmentation using a membrane technique associated with osseointegrated implants. International Journal of Periodontics and Restorative Dentistry* 14, 497-511.
- 13) Tinti, C., Parma-Benfenati, S. & Polizzi, G. (1996)  
*Vertical Ridge augmentation: What is the limit? International Journal of Periodontics and Restorative Dentistry* 16, 221-229.
- 14) Schenk, R.K. (1994)  
*Bone regeneration: Biologic basis. In: Buser, D., Dahlin, C., Schenk, R.K., eds. Guided Bone Regeneration in Implant Dentistry. Berlin: Quintessence, pp. 49-100.*
- 15) Schenk, R.K., Buser, D., Hardwick, W.R. & Dahlin, C. (1994)  
*Healing pattern of bone regeneration in membrane-protected defects. A histologic study in the canine mandible. International Journal of Oral and Maxillofacial Implants* 9, 13-29.