

*introducing...*

# CYTOPLAST MicroDerm™

*Acellular dermal matrix with patented surface micro-cuts*

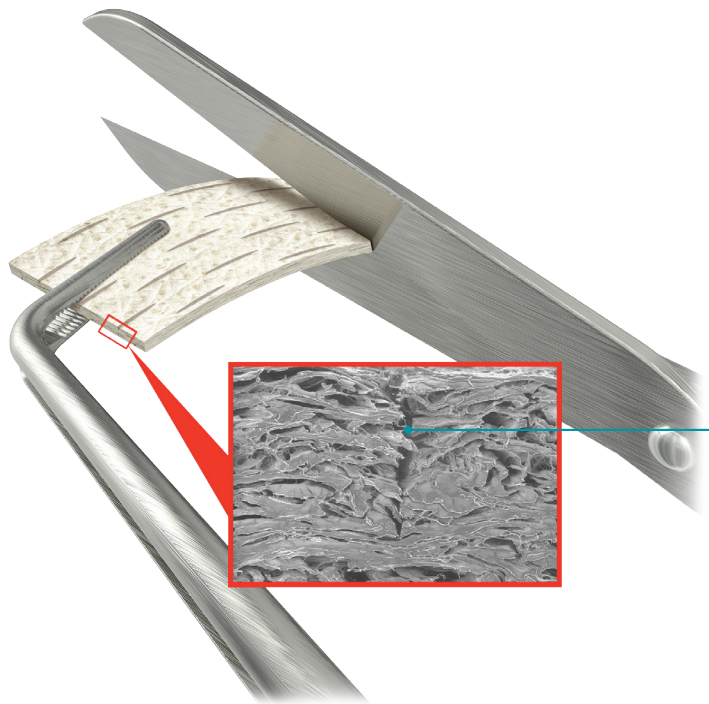


## Benefits of Micro-Cuts

- ▶ Increased surface area at the graft-to-host interface<sup>1</sup>
- ▶ Increased cellular infiltration<sup>1</sup>
- ▶ Increased hydrophilicity of graft
- ▶ Hydrates in 60 seconds
- ▶ Ease of trimming and suture placement



After hydration, Cytoplast MicroDerm™ becomes **soft and pliable.**



### **Dual-sided micro-cuts to increase surface area**

Micro-cut channels shorten pathways for vascularization and increase tissue surface area available for attachment.

“The early healing and soft tissue appearance is really where Cytoplast MicroDerm shines. Tissue never looks this good so early on with traditional allograft.”

*Shaun Rotenberg, DMD, MS*

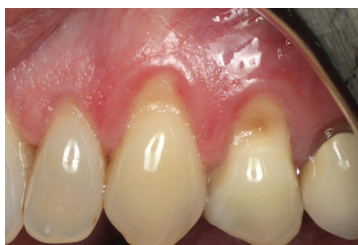1. Marinelli et al. Histologic Evaluation of Wound-Bed Preparedness Following Microsurfaced Skin Grafts for the Treatment of Deep Burn Wounds: Results from a Randomized Controlled Trial. Poster presented at 2023 AMSUS Annual Meeting; February 13, 2023; National Harbor, MD.



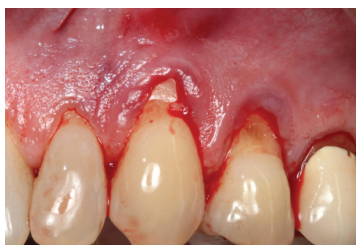# CASE STUDY: Novel Microsurfaced ADM as a Predictable Alternative to the Subepithelial Connective Tissue Graft for Root Coverage Procedures

*This is a 61-year-old female who presented with 3-4 mm recession on teeth 11-12 and 20-22 with minimal attached tissue. There was no root modification, and the site was treated with Cytoplast MicroDerm™ via a vestibular tunnel access approach and sutured with Glycolon™. The patient was treated with a traditional connective tissue graft on the same teeth on the right side and stated that this was a much better experience.*

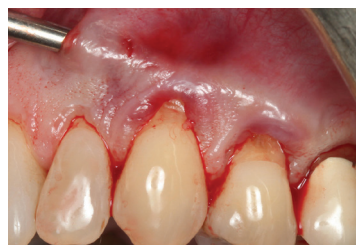Case Photos Provided by Shaun Rotenberg, DMD



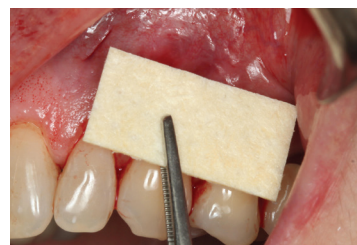1a. Pre-op



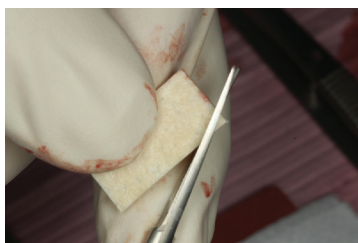
2a. Incisions



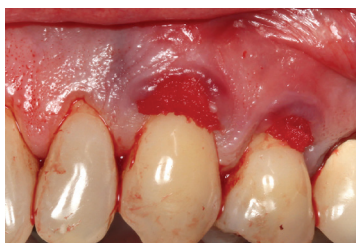3a. Tunnel



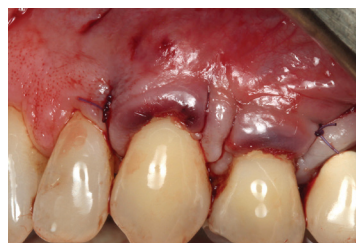4a. Graft



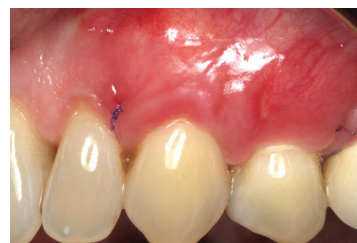5a. Trimming graft



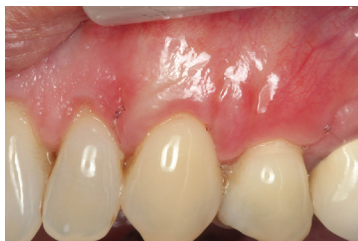6a. Graft in place



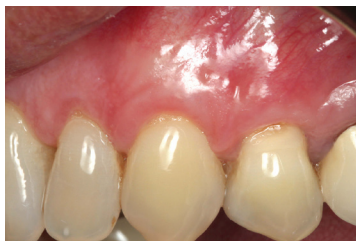7a. Sutured



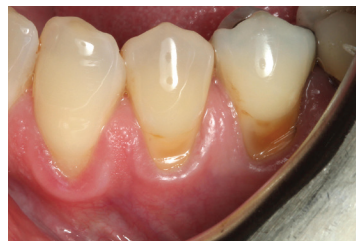8a. Two weeks post-op



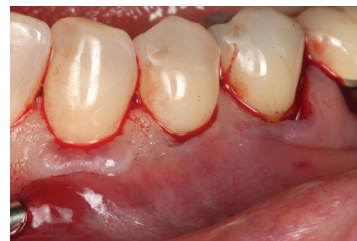9a. Four weeks post-op



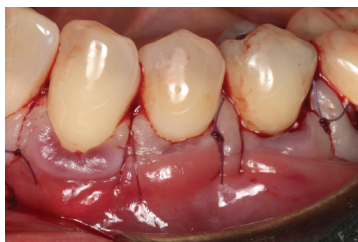10a. Four months post-op



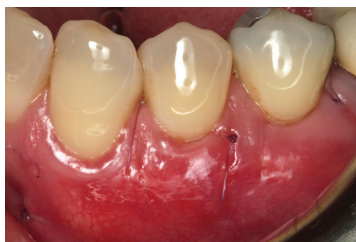1b. Pre-op.



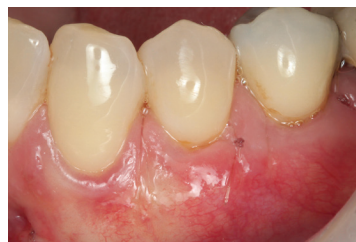2b. Tunnel



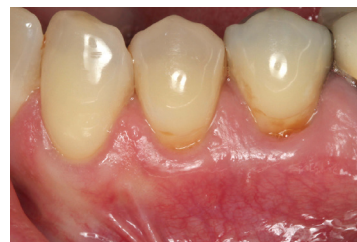3b. Sutured



4b. Two weeks post-op



5b. Four weeks post-op



6b. Four months post-op

## Cytoplast MicroDerm™ Keys to Success for Tunneling

Tips courtesy of *Dr. Shaun Rotenberg*

1. Once the recipient site has been prepared, select the most appropriate Cytoplast MicroDerm™ size (1x1 cm, 1x2 cm, 1x4 cm, 2x4 cm).
2. Cytoplast MicroDerm™ trims easier when it is dry; it can be trimmed with surgical scissors.
3. Cytoplast MicroDerm™ can be inserted into the recipient site dry or hydrated; however, it is recommended to insert it into the recipient site dry for easier manipulation.
4. If you hydrate Cytoplast MicroDerm™ prior to tunnel insertion, complete hydration generally takes less than 60 seconds.
5. Prolonged hydration over 3 minutes can affect tensile strength of the material in relation to suturing and handling.
6. While not required, tension sutures can be used to pull Cytoplast MicroDerm™ into the recipient pouch or tunnel.
7. To ensure proper adaptation, ensure that there are no folds or twists in the graft material prior to suturing.
8. Once Cytoplast MicroDerm™ is in place and is stabilized, the overlying flap should be coronally advanced and secured tension-free.
9. Cytoplast MicroDerm™ should be completely covered by the overlying flap to achieve ideal results.

### Available Sizes

Thickness = 1.2 mm +/-0.2 mm

	1 cm x 1 cm   <b>CMD1010</b> (1 per box)	<b>\$140</b>
	1 cm x 2 cm   <b>CMD1020</b> (1 per box)	<b>\$200</b>
	1 cm x 4 cm   <b>CMD1040</b> (1 per box)	<b>\$280</b>
	2 cm x 4 cm   <b>CMD2040</b> (1 per box)	<b>\$380</b>

### Technical Specifications

- Acellular dermis meets or exceeds all FDA and AATB guidelines for safety
- Terminally sterilized to a SAL of 10<sup>-6</sup>
- Packaged dehydrated
- No antibiotics, no rinsing
- Not side specific